APCASH 2012

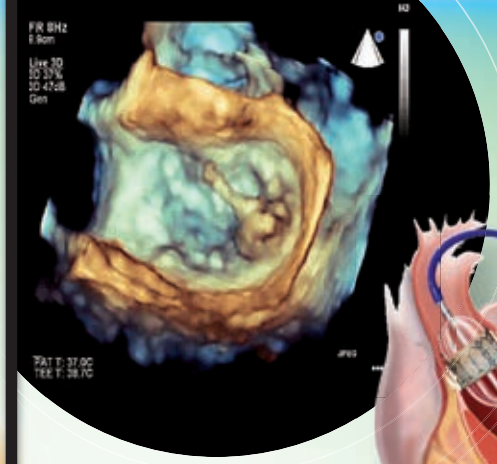

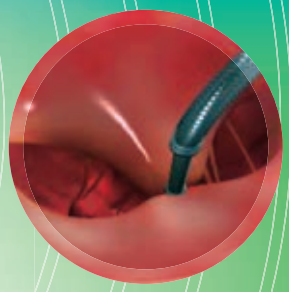

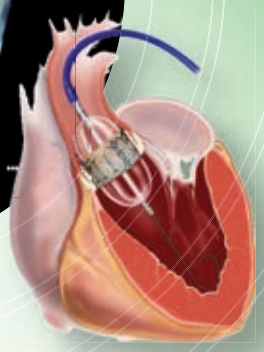

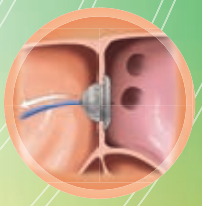

3rd Asia Pacific Congenital & Structural Heart Intervention Symposium 2012

20 – 21 October 2012

Sheraton Hong Kong Hotel & Towers, Hong Kong

Program & Abstract Book

Live Transmission Centres:

Grantham Hospital, Hong Kong

Rigshospitalet, Copenhagen University Hospital, Denmark

Organized by:

Hong Kong Society of Congenital & Structural Heart Disease

Co-organized by:

Cleveland Clinic

Supported by:

Grantham Hospital

Hong Kong College of Cardiology

仁愛醫院 UNION HOSPITAL Union Hospital

Visit our website now!

www.hongkongcash.org

Conference Secretariat

Ms Adele Chan / Ms Lynn Lam / Ms Queenie Wong

MCI Hong Kong, Suites 2807-9, Level 28, Two Chinachem Exchange Square, 338 King's Road, North Point, Hong Kong

Tel: (852) 2911 7923 Fax: (852) 2838 7114 E-mail: apcash@mci-group.com

INTRODUCING

EnligHTN™

MULTI-ELECTRODE RENAL DENERVATION SYSTEM

A Predictable Pattern 4 Renal Denervation.

ONE MONTH CLINICAL DATA[1]

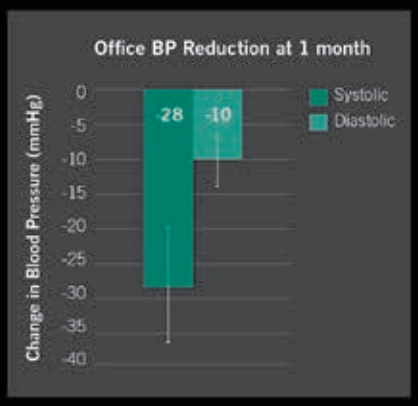

- No major complications
- - 28/10 blood pressure reduction
- 78% of patients with ≥ 10 mmHg in SBP reduction
- 41% of patients with a SBP of < 140mmHg

ST. JUDE MEDICAL
MORE CONTROL. LESS RISK.

SJMenligHTN.com

References

1. Worthley S, Worthley M, et al. EnligHTN I: Safety and efficacy of a novel multi-electrode renal denervation catheter in patients with resistant hypertension: a first-in-man multi-center study. Presented at: European Association of Percutaneous Cardiovascular Interventions, euroPCR 2012 Congress, Paris, France, May 15-18, 2012.

Product referenced is approved for CE Mark.

IPN 2320-12

Table of Content

Welcome Message

It is my great pleasure to welcome you to the 3rd Asia Pacific Congenital & Structural Heart Intervention Symposium (APCASH) on 20-21 October 2012 at the Sheraton Hong Kong Hotel & Towers.

The last APCASH conference in 2011 was well received with participants from 19 regions worldwide. The Organizing Committee has been most encouraged by the many positive feedbacks received. It could never come to fruition without your support, and your continuous support is definitely a huge vote of confidence for us to keep hosting this annual conference.

This year marks the inaugural cooperation with Cleveland Clinic, USA, aiming to provide a higher level of exchange on discussions and insights on congenital and structural heart interventions. We promise to have another stimulating scientific program.

Our program highlights include interventional cardiovascular imaging, new ASD/VSD/PFO closure devices, percutaneous left atrial appendage occlusion, transcatheter aortic valvular implantation and catheter-based treatment for mitral regurgitation. We will again have the live transmissions from Copenhagen University Hospital (Denmark) and Grantham Hospital (Hong Kong).

I am confident this 2-day comprehensive program shall provide opportunities for professional development, networking and broadening your horizons.

I look forward to welcoming you in October 2012!

Dr Steven SL Li
Program Director
APCASH 2012

Congratulatory Messages

It gives me great pleasure to offer my congratulations to the Hong Kong Society of Congenital and Structural Heart Disease on its hosting of the 3rd Asia Pacific Congenital and Structural Heart Intervention Symposium.

This annual Symposium has become an important platform for cardiologists and allied health professionals to exchange experience and ideas, and to learn about the latest advances in cardiac-related technology and services. In bringing together local and international experts, the Symposium also provides a valuable opportunity for cardiac professionals to build new connections with their peers from across the globe.

In Hong Kong, heart disease is the second-leading cause of mortality, with more than 6,000 deaths each year over the past five years. The number of in-patient discharges and deaths due to ischaemic heart disease in Hospital Authority has increased from about 25,000 in 2006 to over 30,000 in 2010. Further, with society trending towards less healthy eating habits, more sedentary lifestyles and increased work stress, the challenges in tackling this major health issue are expected to grow.

The Hospital Authority and the Society share a common goal in their determination to make continual progress in improving cardiac health in Hong Kong. In providing a forum for institutions and professionals to explore opportunities for new collaborative initiatives, the Symposium is playing a major role in creating the synergies required to achieve new breakthroughs.

I wish the Symposium every success. Its many contributions to the advancement of cardiac knowledge and medical procedures will undoubtedly serve to improve heart-related health for people in Hong Kong and beyond.

Dr P Y Leung
Chief Executive
Hospital Authority

Congratulatory Messages

On behalf of the Faculty of Medicine, The Chinese University of Hong Kong, I would like to extend my warmest congratulation to the Hong Kong Society of Congenital and Structural Heart Disease on the successful organization of the 3rd Asia Pacific Congenital & Structural Heart Intervention Symposium 2012. As a Paediatrician, I am fully aware of the importance of congenital heart disease, which affects close to 1% of all newborns. This, plus the acquired structural heart conditions is imposing a heavy burden of disease to the patients, their families, and society. The management of congenital and structural heart conditions in the past invariably required open surgery, which is often complicated, expensive, and risky. With the advances in minimally invasive cardiac intervention, the management of many of these heart conditions has now become less invasive, safer and less traumatic. In this 2-day symposium, we will be hearing from experts, both local and from overseas, the latest developments in this expanding field. Like all the participants, I look forward to learning from them new knowledge and skills that will benefit the many patients with congenital and structural heart diseases.

TF FOK, Dean
Faculty of Medicine
The Chinese University of Hong Kong

Organizing Committee & Faculty

Program Director

Steven SL Li *(Hong Kong)*

Program Co-Directors

Boron CW Cheng *(Hong Kong)*
James Thomas *(USA)*
Yat-yin Lam *(Hong Kong)*
Gabriel WK Yip *(Hong Kong)*
Lars Søndergaard *(Denmark)*

Organizing Committee

Anna KY Chan *(Hong Kong)*
Kwok-keung Ho *(Hong Kong)*
Maurice P Leung *(Hong Kong)*
Francis SF Yiu *(Hong Kong)*
Kam-tim Chan *(Hong Kong)*
Patrick TH Ko *(Hong Kong)*
Betty YK Tang *(Hong Kong)*
Wilson WM Chan *(Hong Kong)*
Cathy TF Lam *(Hong Kong)*
Man-ching Yam *(Hong Kong)*

Overseas Faculty

Mario Evora *(Macau)*
Wei Gao *(China)*
Nikolaj Ihlemann *(Denmark)*
U-po Lam *(Macau)*
Jan-malte Sinning *(Germany)*
James Thomas *(USA)*
Jou-kou Wang *(Taiwan)*
Olaf Franzen *(Denmark)*
Brian Griffin *(USA)*
Saibal Kar *(USA)*
Lan Hieu Nguyen *(Vietnam)*
Lars Søndergaard *(Denmark)*
Murat Tuzcu *(USA)*
Yu-mei Xie *(China)*
Yun-ching Fu *(Taiwan)*
Hidehiko Hara *(Japan)*
Xiang-qing Kong *(China)*
Peter Ruygrok *(New Zealand)*
Lars Svensson *(USA)*
Niels Vejlstrup *(Denmark)*

Local Faculty

Kam-tim Chan *(Hong Kong)*
Adolphus KT Chau *(Hong Kong)*
Shui-wah Chiu *(Hong Kong)*
Katherine YY Fan *(Hong Kong)*
Patrick TH Ko *(Hong Kong)*
Yat-yin Lam *(Hong Kong)*
Michael KY Lee *(Hong Kong)*
Steven SL Li *(Hong Kong)*
Tak-sun Tse *(Hong Kong)*
Chi-ming Wong *(Hong Kong)*
Shou-pang Wong *(Hong Kong)*
Francis SF Yiu *(Hong Kong)*
Joseph YS Chan *(Hong Kong)*
Boron CW Cheng *(Hong Kong)*
Pak-cheung Chow *(Hong Kong)*
Kwok-keung Ho *(Hong Kong)*
Ryan LY Ko *(Hong Kong)*
Yuk-kong Lau *(Hong Kong)*
Sum-kin Leung *(Hong Kong)*
Chiu-on Pun *(Hong Kong)*
Kin-lam Tsui *(Hong Kong)*
Dora ML Wong *(Hong Kong)*
Chris KY Wong *(Hong Kong)*
Cheuk-man Yu *(Hong Kong)*
Wilson WM Chan *(Hong Kong)*
Chung-seung Chiang *(Hong Kong)*
Liang Chow *(Hong Kong)*
On-hing Kwok *(Hong Kong)*
Cathy TF Lam *(Hong Kong)*
Maria SH Lee *(Hong Kong)*
Maurice P Leung *(Hong Kong)*
Kin-ming Tam *(Hong Kong)*
Ping-tim Tsui *(Hong Kong)*
John TH Wong *(Hong Kong)*
Gabriel WK Yip *(Hong Kong)*

Biography of Speakers

Boron CW Cheng *(Hong Kong)*

Dr Boron CW Cheng is the founding president of Hong Kong Society of Congenital and Structural Heart Disease (HKCASH). He is also the Honorary Clinical Assistant Professor of Department of Medicine and Therapeutics of Chinese University of Hong Kong & Honorary Consultant Cardiologist of Kwong Wah Hospital. He graduated from Faculty of Medicine, The University of Hong Kong in 1992. After finished his cardiology training at Queen Elizabeth Hospital (QEH), he received his overseas training in Adult Congenital Heart Disease Intervention at Medical School of Stanford University, CA, USA from 2001 to 2002. He was the director of Congenital & Structural Heart Disease Interventional Service in QEH from 2003 to 2008 & director of Echocardiology Service in QEH from 2005 to 2008. In 2008, Dr Cheng and other peers established the HKCASH. His special interest is in the field of structural and congenital heart disease intervention.

Olaf Franzen *(Denmark)*

Dr Olaf Franzen is currently an interventional consultant in Rigshospitalet, Copenhagen Denmark and as Locum consultant in the Royal Brompton Hospital, London UK. He has extensive experience in echocardiography and heart catheterization in adult congenital and structural heart diseases like ASD closure, VSD closure , LAA occlusion, Duct occlusion, closure of aterio-venous fistula, stent implantation in isthmus stenosis or peripheral pulmonary stenosis, valvuloplasty of mitral or aortic stenosis, closure of paravalvular leaks in transfemoral or transapical approach, percutaneous closure of iatrogenic and post-infarct VSD, Melody valve implantation in pulmonary stenosis, percutaneous and transapical aortic valve implantation with different types of valves, first percutaneous treatment of tricuspid regurgitation with MitraClip system, largest worldwide experience in percutaneous treatment of mitral regurgitation (more than 100 cases with the MitraClip system). He also has extensive experience as speaker on international congresses.

Yun-ching Fu *(Taiwan)*

Dr Yun-Ching Fu graduated from National Yang-Ming University in Taipei, Taiwan in 1989. He was a general practitioner (1989-1993), pediatric resident (1993-1996) and cardiology fellow (1996-1998) at Taipei Veterans General Hospital. He completed PhD in the Institute of Clinical Medicine of National Yang-Ming University (2000-2003). He received interventional training in the University of Chicago Children's hospital under the instruction of Dr. Ziyad M. Hijazi (2004). He is currently the chief of Department of Pediatrics in Taichung Veterans General Hospital and the associate professor in National Yang-Ming University. He is interested in interventional therapy of congenital and structural heart diseases.

Brian Griffin *(USA)*

Dr Griffin has been a cardiologist at the Cleveland Clinic in Cleveland, Ohio since 1993. Cleveland Clinic has been voted the #1 hospital for cardiovascular care for the last 18 years by US News and World Report. Dr Griffin is Head, Section of Cardiovascular Imaging in the Heart and Vascular Institute, Cleveland Clinic since October 1 this year and Physician Director of Development, Heart and Vascular Institute, Cleveland Clinic since 2004. Prior to this, he was Director of the Cardiovascular Disease Training Program since 1994. From 2003-6, he was Vice-Chairman, Department of Cardiovascular Medicine, Cleveland Clinic and has held the John and Rosemary Brown Endowed Chair in Cardiovascular Medicine at Cleveland Clinic since 2007.

Dr Griffin graduated in medicine in 1979 from University College Galway, National University of Ireland. After completing medical training in Galway and Dublin, he trained at Guy's Hospital, London and at Cedars-Sinai Medical Center, Los Angeles. He was a clinical fellow in cardiology at Boston University Medical Center from 1987-9 and at the Massachusetts General Hospital, Boston from 1989-91. From 1991-93, he was on faculty at Dartmouth Medical School.

Biography of Speakers

Dr Griffin is the author of more than 130 publications in cardiology and has edited 3 cardiology textbooks. The Manual of Cardiovascular Medicine that he edits is in its 4th edition and has been translated into Chinese, Spanish, Greek and Portuguese. He is the US Associate Editor for *Heart*, the journal of the British Cardiac Society. He received the Stoke's Medal of the Irish Cardiac Society in 2002 and was the recipient of the Medtronic Award for Medicine, Nursing and Health Sciences from the National University of Ireland Galway in 2011.

Nikolaj Ihlemann *(Denmark)*

Cardiologist since 2007 and Consulting cardiologist at Rigshospitalet, University hospital of Copenhagen, since 2009.

Ecocardiographer with special interest and experience in transcatheter valve therapy, including TAVI, Mitraclip, ASD closure device, LAA occluders.

Saibal Kar *(USA)*

Saibal Kar, MD is an interventional cardiologist in the Cardiology Division of the Department of Medicine at Cedars-Sinai Medical Center, where he is also the Director of Interventional Cardiac Research.

An astute clinician and teacher, Dr. Kar is a skilled interventional cardiologist with a special expertise in valvuloplasty and congenital heart disease. His research interests are focused on coronary restenosis, device development and the advancement of percutaneous techniques in the treatment of congenital and valvular heart diseases. Involved in both clinical and experimental research, Dr. Kar's clinical work has included publishing data on different aspects of angioplasty for the treatment of acute myocardial infarction. In the experimental lab, he has done original work on newer drug eluting stents for the prevention of restenosis of coronary stents, and he recently developed a new drug eluting stent, which is being used in a clinical trial in Germany.

Dr. Kar has published his clinical and experimental work in full manuscript form in peer-reviewed journals and has presented at numerous international meetings. He has written book chapters in *Interventional Cardiology* and *General Cardiology*, and he was instrumental in the startup of a special program of percutaneous closure of atrial and ventricular septal defects.

A board certified interventional cardiologist, Dr. Kar is a fellow and active member of the American College of Cardiology and American Heart Association. He is also member of other professional organizations, including the Society of Coronary Angiography and Intervention, American College of Physicians, American Medical Association and Cardiology Society of India. He also serves on the Scientific Advisory Committee of the World Congress of Heart Failure.

Dr. Kar earned his medical degree from Nil Ratan Sircar Medical College in Calcutta, India. Following his internship, he completed his residency in medicine and his fellowship in cardiology at the Postgraduate Institute of Medical Education and Research in Chandigarh, India. After serving for a short time as Assistant Professor at this institute, he began working as an interventional cardiology fellow at the Epworth Hospital in Melbourne, Australia. Dr. Kar came to the United States and repeated his residency in medicine at the West Los Angeles Veterans Administration Hospital, and he completed his cardiology and interventional cardiology fellowship at Cedars-Sinai Medical Center. In view of his academic merits and previous accomplishments, the American Board of Medicine gave special consideration to shorten his period of residency and fellowship.

Biography of Speakers

Ryan LY Ko *(Hong Kong)*

Dr. Ryan Ko graduated from the Hong Kong University in 2000. He trained in cardiology and interventional cardiology at the Queen Mary Hospital in Hong Kong and obtained his fellowship with the Hong Kong College of Physician in 2007. He later completed an Adult Congenital Heart Disease interventional fellowship at the Royal Brompton Hospital in London and subsequently a Structural Heart Disease interventional fellowship at the National Heart Hospital in London.

His special interests include Transcatheter Aortic Valve Implantation, MitraClip repair technology and percutaneous pulmonary valve implantation.

Yat-yin Lam *(Hong Kong)*

Prof. Lam graduated from University of Hong Kong with John Anderson Gray Medal in 1999. He received his general medical and basic cardiology training at Prince of Wales Hospital and obtained his fellowship of Hong Kong Academy of Medicine in the Specialty of Cardiology in 2006. He further underwent advanced clinical and research training in the field of adult congenital heart disease in Royal Brompton Hospital, London. In 2008, he joined the Chinese University of Hong Kong as associate professor in cardiology and earned a Doctor of Medicine (MD) degree in 2011. He is well recognized as one of the leading physicians performing interventional procedures for structural heart diseases in Hong Kong. He is also an active researcher and his work mainly focuses on the imaging and interventional skills in adult patients with congenital and structural heart diseases. To date, he has authored or co-authored over 90 peer-reviewed publications in international journals including *American Journal of Cardiology, Heart* and *European Heart Journal* and *Journal of American College of Cardiology*. In addition, Dr Lam is currently the associate editor of International Journal of Cardiology (Cardiac Interventions) and the vice president of Hong Kong Society of Congenital and Structural Heart Disease. He was elected as a fellow of the American College of Cardiology (FACC), European Society of Cardiology (FESC) and Royal College of Physicians (FRCP) in recognition of his contributions to the field of cardiovascular medicine.

Michael KY Lee *(Hong Kong)*

Dr Michael KY Lee is currently the Consultant Cardiologist at the Division of Cardiology, Department of Medicine, Queen Elizabeth Hospital, Hong Kong and Honorary Clinical Assistant Professor of the Li Ka Shing Faculty of Medicine, University of Hong Kong. He graduated from Faculty of Medicine, The University of Hong Kong in 1991. He received his overseas training in Interventional Cardiology at the Brigham & Women's Hospital, Harvard Medical School, Boston, USA from 1999 – 2000. In 2010, Dr Lee established the Hong Kong Society of Transcatheter Endocardiovascular Therapeutics (HKSTENT), the only charitable interventional cardiology organization in Hong Kong, and became the Founding President. He is also the "Visiting Professor" of 2nd Municipal People's Hospital of Foshan and Southeast University XuZhou Hospital, China, "Visiting Lecturer" of the School of Chinese Medicine, Hong Kong Baptist University and Honorary Consultant of Conde S. Januario General Hospital, Macau. He is also a faculty member of the Chinese Cardiovascular Research Foundation (CCRF) and council member of TCT International Council, Cardiovascular Research Foundation (CRF), New York, USA. In Queen Elizabeth Hospital, he is the doctor-in-charge of the Cardiac Ambulatory Care Centre and the Programme Director of Basic Physician Training of Kowloon Central Cluster. His special interests include Interventional Cardiology (Coronary and Valvular Interventions) and AMI/ACS management. He helped to establish the TAVI program in Queen Elizabeth Hospital and performed the first TAVI case in Hong Kong in 2010. He is currently helping the Hospital Authority to establish Primary PCI program and TAVI program in Hong Kong.

Biography of Speakers

Steven SL Li *(Hong Kong)*

Dr. Li is current president of Hong Kong Society of Congenital and Structural Heart Disease. He is the consultant cardiologist and director of the Heart Centre of Union Hospital in Hong Kong. He is also the Honorary Clinical Assistant Professor of Department of Medicine and Therapeutics of Chinese University of Hong Kong.

Dr. Li graduated from the medical school of University of Hong Kong in 1989. He finished his basic training in internal medicine and cardiology at Queen Elizabeth Hospital and then he received one year training in advanced cardiology and interventional cardiology at The Cleveland Clinic Foundation in USA. He was also trained in cardiac MRI and cardiac CT in Germany and USA respectively.

Dr. Li is an interventional cardiologist and is interested in various areas of transcatheter therapeutics in cardiology including coronary artery disease, peripheral vascular disease and adult congenital heart disease.

Lan Hieu Nguyen *(Vietnam)*

Dr Lan Hieu Nguyen is the Vice Director Cardiac center of Hanoi Medical University hospital since 2010, Co-Director of Cardiac Cath Lab in Hanoi Heart hospital, Hanoi, Vietnam since 2009 and Vice director of Cardiac Cath Lab in Vietnam heart institute, Bach Mai hospital, Hanoi, Vietnam since 2008. He sets up the congenital heart disease programme in Thanh Hoa general hospital, Thanh Hoa, Vietnam since 2009, sets up the congenital heart disease programme in Nghe An general hospital, Nghe An, Vietnam since 2008, sets up the cardiology intervention programme in Danang hospital, Danang, Vietnam since 2006 and sets up the congenital heart disease programme in Bach Mai hospital, Hanoi Vietnam since 2003. He practices in Vietnam Heart Institute, Bach Mai hospital, Hanoi, Vietnam and delivers Lecture in Hanoi Medical University since 2000.

He graduated PHD from Hanoi medical University in 2008. He was visiting physician in pediatric cardiology, UCSF, San Francisco, United States in 2002. In 2000 – 2001, he had Fellowship in congenital heart disease intervention, Marie Lannelongue hospital, Paris, France. In 1997 – 1998, he had Fellowship in cardiology intervention, Ranguei hospital, Toulouse, France. In 1995 – 1999, he had Fellowship in cardiology, Bach Mai hospital, Hanoi, Vietnam. In 1989 – 1995, he was Student at the Hanoi Medical University, Hanoi, Vietnam.

For achievement, in 2002, he obtained Complimentary certificate for inititive in studying method. He obtained Prize in cardiology intervention for young Vietnamese investigator award in 2003 and First prize for young investigator award in all Vietnamese science universities in 2004. In 2004, he also obtained AFSUMB 2004 Award, in recognition of its distinguished contribution of the 7th Congress of the Asian Federation of societies for Ultrasound in Medicine and Biology, Utsunomiya, Japan. In 2008, he obtained the 2nd prize winner for Asean young investigator award in the 17th ASEAN congress of Cardiology.

Peter Ruygrok *(New Zealand)*

Peter Ruygrok graduated Bachelor of Science in mathematics in 1979, Bachelor of Medicine & Bachelor of Surgery in 1986 and more recently Doctor of Medicine, from the University of Auckland. He trained in cardiology at Green Lane Hospital, gaining his fellowship of the Royal Australian College of Physicians and then completed an interventional fellowship at the Thoraxcenter in Rotterdam.

He works as a consultant cardiologist and is the Director of Cardiovascular Services at Auckland City Hospital. His special interests include interventional cardiology, cardiac transplantation and research, with over 130 publications. He is an Honorary Professor of the University of Auckland and works part-time at the Auckland Heart Group.

Biography of Speakers

Jan-malte Sinning *(Germany)*

Dr Sinning works in Department of Cardiology University Hospital Bonn Germany.

Lars Søndergaard *(Denmark)*

Lars Søndergaard is a consultant cardiologist, MDSc, specialised in structural and congenital heart diseases. He trained at Rigshospitalet in Copenhagen, as well as at Great Ormond Street Hospital and the Heart Hospital in London. He is involved in the transcatheter valve therapy program at Rigshospitalet in Copenhagen, Denmark. His research interests is mainly focus on TVT and adults with congenital heart diseases.

Lars Svensson *(USA)*

Lars Georg Svensson, MD, PhD is an attending surgeon and Director of the Aorta Center, Director of the Marfan Syndrome and Connective Tissue Disorder Clinic, and Director of Quality and Process Improvement in the Department of Thoracic and Cardiovascular Surgery at Cleveland Clinic. He is also a professor of surgery at Cleveland Clinic Lerner College of Medicine and Case Western Reserve University. Dr. Svensson is board-certified in general, vascular, thoracic and cardiac surgery. He specializes in adult cardiac surgery; cardio-aortic and aortic surgery, including combined valve and aneurysm surgery; minimally invasive mitral and aortic valve surgery; mitral and aortic valve repair operations (including bicuspid valve repairs and modified David Reimplantation operation), blood conservation; prevention of stroke and paralysis after aortic surgery; Marfan syndrome; peripheral vascular surgery; Percutaneous valve surgery; and the Maze procedure. He obtained his medical degree in 1978, a MSc in 1983 and a PhD in 1986 from the University of Witwatersrand, Johannesburg, South Africa. His cardiology, general and vascular surgery training was at the Johannesburg Hospital, followed by cardiovascular surgery training at the Cleveland Clinic Foundation, Cleveland, Ohio, and Baylor College of Medicine in Houston Texas, including cardiothoracic surgery residency. He was Chief of Cardiovascular Surgery at Houston VAMC and worked with Drs. DeBakey and Crawford at Baylor College of Medicine. He was Assistant Professor of Surgery at Baylor College of Medicine, and then Professor of Cardiothoracic Surgery at Tufts, and Instructor at Harvard Medical School while working at the Lahey Clinic in Boston. In 2005 he was made King James IV Professor of Surgery of The Royal College of Surgeons of Edinburgh. He is on numerous committees, including the Society of Thoracic Surgery / American Association for Thoracic Surgery Government Relations Committee, Annals of Thoracic Surgery, and Cleveland Clinic Foundation Surgery Committee. His interests are minimal invasive valve surgery, percutaneous cardiovascular surgery, and brain and spinal cord protection during cardiovascular surgery. His hobbies are photography and sailing.

James Thomas *(USA)*

Born and raised in Oklahoma, Dr. James D. Thomas attended Harvard College (BA summa cum laude in Applied Mathematics) and Harvard Medical School before clinical training at Massachusetts General Hospital and the University of Vermont. He is now the Moore Chair in Cardiovascular Imaging at the Cleveland Clinic and Professor of Medicine and Biomedical Engineering at Case Western Reserve University and serves as lead scientist for ultrasound with NASA. Clinical interests include valvular heart disease and diastolic dysfunction with research interests in cardiac mechanics, application of new echo technology, and space physiology. He is Immediate Past-President of the American Society of Echocardiography, has previously served on the Cardiovascular Board of ABIM, and was co-chairman for the 2007 ACC Annual Scientific Sessions. When not reading echoes, Dr. Thomas enjoys cooking, skiing, scuba diving, and the occasional bungee jump.

Biography of Speakers

Murat Tuzcu *(USA)*

Murat Tuzcu, M.D. is a Professor of Medicine, Vice-Chairman of the Department of Cardiovascular Medicine (Interventional Cardiology) at the Sydell and Arnold Miller Heart & Vascular Institute at the Cleveland Clinic.

Dr. Tuzcu's clinical interests cover a wide range of interventional cardiology patients. In addition to percutaneous treatment of coronary artery disease, his expertise includes catheter-based treatment of valvular heart disease and adult congential heart defects. He is an internationally recognized expert in the emerging field of percutaneous valve repair and replacement. Patients from all over the United States and around the world seek his expertise.

Dr. Tuzcu's current research interests focus on the investigation of catheter-based treatments for valvular heart disease. He holds several patents involving catheter design. Another long term research interest involves the use of various imaging modalities to elucidate the development and progress of atherosclerosis. He has made seminal contributions to the understanding of transplant coronary artery disease and subclinical atherosclerosis using intravascular ultrasound imaging. He had and continues to have leadership roles in landmark studies in his areas of his research interests.

Dr. Tuzcu received his medical degree from Istanbul Medical Faculty in Turkey, where he completed his internship and residency in Internal Medicine. He was then awarded fellowships by Cleveland Clinic in Cardiovascular Disease and Interventional Cardiology. He was a special clinical and research fellow, then a junior faculty at the Massachusetts General Hospital and Harvard Medical School in Boston. He was appointed to Cleveland Clinic as a staff in 1992. He is certified as a Diplomate of the American Board of Internal Medicine in Internal Medicine, Cardiovascular Diseases and Interventional Cardiology.

Dr. Tuzcu is heavily involved in the training of young cardiologist. Through work in the International Center, Dr. Tuzcu is also involved in medical education of doctors from all over the world. He has held several academic appointments including Instructor in medicine and Research at Harvard Medical School, Assistant Professor of Medicine at the University of Pittsburgh and Professor of Medicine at Ohio State University. Currently, he is a Professor of Medicine in the Lerner College of Medicine at Case Western Reserve University.

He has authored or co-authored more than 200 peer-reviewed publications. Dr. Tuzcu has directed or co-directed many national and international symposiums and professional conferences worldwide, and has been an invited lecturer to many others. He was the Chairman of the Scientific Program Committee of the 56th Annual Scientific Sessions in 2007. He is currently on the editorial board of several academic journals.

Dr. Tuzcu is a Fellow in the American College of Cardiology, American Heart Association, Society for Cardiac angiography and Interventions, the American College of Physicians, and a member of the Turkish Society of Cardiology. Dr. Tuzcu was voted into the recent listing of "Best Physicians in America," and is listed in the National Registry of Who's Who.

Niels Vejlstrup *(Denmark)*

Dr. Neils Vejlstrup is currently a Consultant Cardiologist, Department of Cardiology, Rigshospitalet, Copenhagen University Hospital and Head of Rigshospitalet's Pregnency Clinic for Women with Heart Disease; responsible for adults with congenital heart disease; foetal echocardiography, and head of Rigshopitalet's cardiac MRI. His research is interested in heart disease in pregnancy, intracardiac ultrasound, left ventricular diastolic function, myocardial preconditioning and foetal cardiology.

Biography of Speakers

Gabriel WK Yip *(Hong Kong)*

Dr. Yip is currently the Honorary Secretary of the Hong Kong Society of Congenital and Structural Heart Disease. He is an Associate Consultant, Cardiac Medical Unit, Grantham Hospital, Hong Kong and Honorary Clinical Assistant Professor of the Li Ka Shing Faculty of Medicine, University of Hong Kong. Graduated Bachelor of Medicine & Bachelor of Surgery in 1992 with Distinction in Pathology, and Doctor of Medicine in 2004 from University of Sheffield Medical School, UK, Dr. Yip trained in Cardiology at Prince of Wales Hospital, Hong Kong and was a clinical fellow in echocardiography at Mayo Clinic, Rochester, Minnesota from 2001-2. From 2006-2011, he was on faculty at Chinese University of Hong Kong. He is an Associate Editor of Heart Asia and serves in American Society of Echocardiography's FASE Committee. Clinical interests include echo-guided guided interventions in heart failure and adult congenital and structural heart disease.

Program-at-a-Glance

Saturday 20 October 2012

07:45 – 09:00	**Best Abstract Competition** Venue: Ballroom, 3/F	
09:00 – 10:30	**Live Case Transmission from Grantham Hospital – I** Venue: Ballroom, 3/F	
10:30 – 11:00	**Tea Break & Visit Exhibits** Venue: Ballroom, 3/F	
11:00 – 11:30	**Live Case Transmission from Grantham Hospital – II** Venue: Ballroom, 3/F	
11:30 – 12:30		
12:30 – 13:00	**Distribution of lunch boxes*	
13:00 – 13:45	**Symposium on Mitral Valve Disease Interventions** Venue: Ballroom, 3/F	
13:45 – 14:00		
14:00 – 14:15	**APCASH 2012 Opening Ceremony** Venue: Ballroom, 3/F	
14:15 – 15:00	**Live Case Transmission from Rigshospitalet, Copenhagen, Denmark – I** Venue: Ballroom, 3/F	
15:00 – 15:30		
15:30 – 16:00		
16:00 – 16:30	**Live Case Transmission from Rigshospitalet, Copenhagen, Denmark – II** Venue: Ballroom, 3/F	**Tea Break & Visit Exhibits** *(Concurrent with Live Case Transmission from Rigshospitalet, Copenhagen, Denmark – II)* Venue: Ballroom, 3/F
16:30 – 16:55		
16:55 – 17:00		
17:00 – 18:45		
18:45 – 21:00	**Faculty Dinner and Awards Presentation of Best Abstract Competition** *(By invitation)* Venue: Peking Garden Restaurant, 3/F, Star House, 3 Salisbury Road, Tsim Sha Tsui, Kowloon ** Pick-up at Bell Desk, G/F of Sheraton Hong Kong Hotel & Towers at 18:30*	

Sunday 21 October 2012

07:45 – 09:00			
09:00 – 10:30	**Symposium on Aortic Valve Disease** Venue: Ballroom, 3/F		
10:30 – 11:00	**Paravalvular Leak, Post MI VSR and Beyond** Venue: Ballroom, 3/F	**Tea Break & Visit Exhibits** *(Concurrent with Paravalvular Leak, Post MI VSR and Beyond)* Venue: Ballroom, 3/F	
11:00 – 11:30			
11:30 – 12:30			**Press Conference** Venue: Tang Room, 3/F
12:30 – 13:00	**Distribution of lunch boxes*		
13:00 – 13:45	**Medtronic Lunch Symposium – Era of Innovation – TRenD and CoreValve** Venue: Ballroom, 3/F		
13:45 – 14:00			
14:00 – 14:15	**Cases Sharing from the Experts** Venue: Ballroom, 3/F		
14:15 – 15:00			
15:00 – 15:30			
15:30 – 16:00		**Tea Break & Visit Exhibits** *(Concurrent with Best Clinical Case Competition)* Venue: Ballroom, 3/F	**Hands-on Workshop** Venue: Tang Room, 3/F **On-site registration required; number of participants limited*
16:00 – 16:30	**Best Clinical Case Competition** Venue: Ballroom, 3/F		
16:30 – 16:55			
16:55 – 17:00	**Closing Remarks** Venue: Ballroom, 3/F		
17:00 – 18:45			
18:45 – 21:00			

Opening Ceremony

Saturday 20 October 2012 **Ballroom, 3/F, Sheraton Hong Kong Hotel and Towers**

13:45	Delegates and guests to be seated
13:55	Introduction
14:00	Opening Address by Guest of Honor, Prof Tak-fai Fok Dean, Faculty of Medicine, The Chinese University of Hong Kong
14:05	Message by Dr Chris KY Wong President of Hong Kong College of Cardiology
14:08	Message by Prof James Thomas Moore Chair in Cardiovascular Imaging at Cleveland Clinic
14:11	Vote of Thanks by Dr Steven SL Li President of HK Society of Congenital & Structural Heart Disease
14:14	Presentation of Souvenirs & Group Photo of Stage Guests
14:15	End of Program

Scientific Program

Main Conference

	Saturday 20 October 2012 ▪ Morning Session	
	Ballroom, 3/F, Sheraton Hong Kong Hotel and Towers	
07:30	**Registration**	
07:45 – 09:00	**Best Abstract Competition** ***Judges:*** *Kam-tim Chan (Hong Kong), Boron CW Cheng (Hong Kong), Cathy TF Lam (Hong Kong)*	
07:45	Percutaneous Closure of Ascending Aortic Pseudoaneurysm Using Amplatzer Septal Occluder: A Report of Two Cases	Munesh Tomar *(India)*
08:00	Assessment of Left Atrial Appendage Ejection Fraction in Three Dimensions with 64 Slice Computed Tomography	Hidehiko Hara *(Japan)*
08:15	Vascular Plugs: Our Experience from Nine Cases	Manoj Kumar Rohit *(India)*
08:30	Predictors of Residual Functional Tricuspid Regurgitation after Transcatheter Atrial Septal Defect Closure: Importance of Pre-Closure Tricuspid Valve Anatomy	Fang Fang *(Hong Kong)*
08:45	Medical and Surgical Hybrid Therapy for Complex and Cyanotic Congenital Heart Defects Patients with Major Aortopulmonary Collateral Arteries	Yao-ling Ma *(China)*
09:00 – 10:30	**Live Case Transmission from Grantham Hospital – I** ***Chairpersons:*** *Hidehiko Hara (Japan), Maria SH Lee (Hong Kong), Dora ML Wong (Hong Kong)* ***Panelists:*** *Boron CW Cheng (Hong Kong), Steven SL Li (Hong Kong), Ping-tim Tsui (Hong Kong), Cheuk-man Yu (Hong Kong)* ***On-line factoids relevant to the cases presented:*** *Dr. Andrew KY Ng (Hong Kong)*	
09:00 – 10:15	Discussion of Live Case (I) – LAA Occluder	Saibal Kar *(USA)* / Yat-yin Lam *(Hong Kong)* / Gabriel WK Yip *(Hong Kong)* / Francis SF Yiu *(Hong Kong)*
10:15	LAA Occlusion: What You Need to Know	Yat-yin Lam *(Hong Kong)*
10:30 – 11:00	**Tea Break & Visit Exhibits**	
11:00 – 12:30	**Live Case Transmission from Grantham Hospital – II** ***Chairpersons:*** *Adolphus KT Chau (Hong Kong), Jou-kou Wang (Taiwan)* ***Panelists:*** *Yun-ching Fu (Taiwan), Lan Hieu Nguyen (Vietnam), Yu-mei Xie (China)* ***On-line factoids relevant to the cases presented:*** *Dr. Andrew KY Ng (Hong Kong)*	
11:00	Discussion of Live Case (II & III) – ASD & Perimembranous VSD	Wei Gao *(China)* / Ryan LY Ko *(Hong Kong)* / Yat-yin Lam *(Hong Kong)* / Gabriel WK Yip *(Hong Kong)*
11:50	Percutaneous Transcatheter of Perimembranous Ventricular Septal Defect with Ductal Occluder in Vietnam	Lan Hieu Nguyen *(Vietnam)*
12:00	PFO Closure after the CLOSURE I Trial	Peter Ruygrok *(New Zealand)*
12:10	The New Era of the Interventional Imager: Multimodality Imaging in the Cath Lab	Murat Tuzcu *(USA)*
	**12:30 – 13:00 for distribution of lunch boxes*	

Scientific Program

Main Conference

	Saturday 20 October 2012 ▪ Afternoon Session	
	Ballroom, 3/F, Sheraton Hong Kong Hotel and Towers	
13:00 – 13:45	**Symposium on Mitral Valve Disease Interventions** ***Chairpersons:*** *On-hing Kwok (Hong Kong), Steven SL Li (Hong Kong), Kin-ming Tam (Hong Kong)*	
13:00	Who will Benefit from Percutaneous Management of Mitral Regurgitation? An Imaging Guide to Management	James Thomas *(USA)*
13:20	Complications and Tips & Tricks of MitraClip / Leading Devices for Treating Mitral Valve Regurgitation	Saibal Kar *(USA)*
14:00 – 14:15	**APCASH 2012 Opening Ceremony**	
14:15 – 15:00	**Live Case Transmission from Rigshospitalet, Copenhagen, Denmark – I** ***Chairpersons:*** *Wilson WM Chan (Hong Kong), Boron CW Cheng (Hong Kong)* ***Panelists:*** *Shui-wah Chiu (Hong Kong), Ryan Ko (Hong Kong), U-po Lam (Macau)*	
14:15	Discussion of Live Case (I) – MitraClip	Olaf Franzen *(Denmark)* / Nikolaj Ihlemann *(Denmark)*
14:45	Surgical Techniques of Mitral Valve Repair	Lars Svensson *(USA)*
15:00 – 17:00	**Live Case Transmission from Rigshospitalet, Copenhagen, Denmark – II** ***Chairpersons:*** *Kam-tim Chan (Hong Kong), Yat-yin Lam (Hong Kong)* ***Panelists:*** *Kwok-keung Ho (Hong Kong), Michael KY Lee (Hong Kong), Murat Tuzcu (USA)*	
15:00	Discussion of Live Case (II) – CoreValve (Valve-in-Valve)	Lars Søndergaard *(Denmark)* / Niels Vejlstrup *(Denmark)*
15:45	Evolution of Aortic Valve Surgery	Lars Svensson *(USA)*
16:05	Procedural Guidance of TAVR: How to Assure it Goes Right and What to Do if it Doesn't	James Thomas *(USA)*
16:25	TAVI 2012 and Beyond	Murat Tuzcu *(USA)*
16:45	Hybrid Approach to Aortic Arch Surgery	Lars Svensson *(USA)*
16:00 – 16:30	**Tea Break & Visit Exhibits** ***(Concurrent with Live Case Transmission from Rigshospitalet, Copenhagen, Denmark – II)***	
18:45	**Faculty Dinner and Awards Presentation of Best Abstract Competition *(By invitation)*** **Venue:** Peking Garden Restaurant, 3/F, Star House, 3 Salisbury Road, Tsim Sha Tsui, Kowloon ** Pick-up at Bell Desk, G/F of Sheraton Hong Kong Hotel & Towers at 18:30*	

Scientific Program

Main Conference

	Sunday 21 October 2012 ▪ Morning Session	
	Ballroom, 3/F, Sheraton Hong Kong Hotel and Towers	
08:30	**Registration**	
09:00 – 10:30	**Symposium on Aortic Valve Disease** ***Chairpersons:*** *Yuk-kong Lau (Hong Kong), Chiu-on Pun (Hong Kong), Kin-lam Tsui (Hong Kong), Gabriel WK Yip (Hong Kong), Francis SF Yiu (Hong Kong)*	
09:00	Challenges in the Clinical and Echocardiographic Assessment of AS: Who is a Candidate for TAVR?	Brian Griffin *(USA)*
09:30	CoreValve Implantation : Tips & Tricks	Jan-malte Sinning *(Germany)*
10:00	Clinical Value of 3D Echo: Volumes and Valves	James Thomas *(USA)*
10:30 – 11:00	**Tea Break & Visit Exhibits** ***(Concurrent with Paravalvular Leak, Post MI VSR and Beyond)***	
10:30 – 13:00	**Paravalvular Leak, Post MI VSR and Beyond** ***Chairpersons:*** *Chung-seung Chiang (Hong Kong), Liang Chow (Hong Kong), Sum-kin Leung (Hong Kong)*	
10:30	Device Closure of Paravalvular Leak- Imaging in Patient Selection and Device Placement	Brian Griffin *(USA)*
10:55	Diagnosis and Management of Post-myocardial Infarction Ventricular Septal Defects	Peter Ruygrok *(New Zealand)*
11:20	Taped CASH Case – Perimembranous Ventricular Septal Defect Closure	Yu-mei Xie *(China)*
11:45	Pulmonary Valve Disease in Congenital Heart Disease: How Bad is the Problem?	Brian Griffin *(USA)*
12:10	Taped CASH Case – Transcatheter Pulmonary Valve Implantation	Lan Hieu Nguyen *(Vietnam)*
	**12:35 – 13:00 for distribution of lunch boxes*	

Scientific Program

Main Conference

	Sunday 21 October 2012 ▪ Afternoon Session	
	Ballroom, 3/F, Sheraton Hong Kong Hotel and Towers	
13:00 – 14:00	**Medtronic Lunch Symposium – Era of Innovation – TRenD and CoreValve** ***Chairpersons:*** *Joseph YS Chan (Hong Kong), Katherine YY Fan (Hong Kong), Tak-sun Tse (Hong Kong), Chi-ming Wong (Hong Kong)*	
13:00	TRenD and its Expanding Indications	Steven SL Li *(Hong Kong)*
13:30	Interesting CoreValve Cases from Hong Kong	Yat-yin Lam / Michael KY Lee *(Hong Kong)*
14:00 – 15:30	**Cases Sharing from the Experts** ***Chairpersons:*** *Mario Evora (Macau), Xiang-qing Kong (China), Maurice P Leung (Hong Kong), Gabriel WK Yip (Hong Kong)*	
14:00	MitraClip	Boron CW Cheng *(Hong Kong)*
14:15	EnligHTN	Steven SL Li *(Hong Kong)*
14:30	TAVI – "Lady with an Exceptional Anatomy"	Jan-malte Sinning *(Germany)*
14:45	Transcatheter Closure of Left Ventricular Posterior Wall Rupture After Myocardial Infarction	Yun-ching Fu *(Taiwan)*
15:00	Device Closure of LV Lateral Wall Rupture Case	Peter Ruygrok *(New Zealand)*
15:15	Left Atrial Appendage Closure	Yat-yin Lam *(Hong Kong)*
15:30 – 16:00	**Tea Break & Visit Exhibits** ***(Concurrent with Best Clinical Case Competition)***	
15:30 – 16:55	**Best Clinical Case Competition** ***Chairperson:*** *Patrick TH Ko (Hong Kong)* ***Judges:*** *Sum-kin Leung (Hong Kong), Steven SL Li (Hong Kong), James Thomas (USA), Shou-pang Wong(Hong Kong), Gabriel WK Yip (Hong Kong)*	
15:30	Case of SOB in a 83 Year Old Lady	Daniel Fong *(Hong Kong)*
15:45	How to Treat a Mitral Paravalvular Leak?	Jason Ko *(Hong Kong)*
16:00	Coarctation of Aorta: My Disaster	Manoj Kumar Rohit *(India)*
16:15	Residual Severe Echo Contrast After Successful Implantation of ACP in a Patient	Jung-sun Kim *(Korea)*
16:30	Man Against the Rock	Adrian Cheong *(Hong Kong)*
16:45	Percutaneous Transcatheter Embolization of Pulmonary Arteriovenous Fistula	Yao-ling Ma *(China)*
16:55	**Closing Remarks** ***President of Hong Kong Society of Congenital & Structural Heart Disease***	Steven SL Li *(Hong Kong)*

Conference Information

3rd Asia Pacific
Congenital & Structural Heart Intervention Symposium 2012
APCASH 2012

Date and Time:
Saturday 20 October 2012 07:45 – 17:00
Sunday 21 October 2012 09:00 – 17:00

Venue:
Sheraton Hong Kong Hotel & Towers, Hong Kong

Organized by: Hong Kong Society of Congenital & Structural Heart Disease
Co-organized by: Cleveland Clinic
Supported by: Grantham Hospital, Hong Kong College of Cardiology, Union Hospital

Live Transmission Centres

Grantham Hospital, Hong Kong
Rigshospitalet, Copenhagen University Hospital, Denmark

Conference Secretariat

Ms Adele Chan / Ms Lynn lam / Ms Queenie Wong
MCI Hong Kong
Suites 2807-09, Two Chinachem Exchange Square, 338 King's Road, North Point, Hong Kong
Tel: (852) 2911 7923 Fax: (852) 2838 7114 Email: apcash@mci-group.com

Official Language

The official language is English. No simultaneous translation will be provided.

Registration

Registration counter is located at pre-function area of Ballroom, 3/F. Please present the official receipt at the registration counter to collect conference bag and program book.

Opening hours of registration counters:

Saturday 20 October 2012	**07:00 – 17:00**
Sunday 21 October 2012	**08:30 – 16:00**

For on-site registration, payment can be made in cash (HK Dollars) or local HK cheque. Official receipt will be issued and forwarded to respective delegate after the Conference.

Registration fee for on-site registrant of Conference is as follows:

Category	Rate
Physicians	**HK$3,000**
Fellows / Trainees	**HK$1,500**
Allied Health Professionals	**HK$1,500**

Badge

Color-coded badges will be used during the Conference. For identification purpose and admission to the Opening Ceremony, scientific sessions and exhibition, delegates are requested to wear their badges which will be available upon registration.

Certificate of Attendance

Certificate of Attendance will be issued at the time of registration to delegates who are preregistered. For on-site registrants, Certificate of Attendance will be available at the end of the Conference.

Exhibition

In conjunction with the Conference, an exhibition featuring the latest products, equipments and educational materials in cardiac diseases will be held at the same time at the Ballroom, 3/F. Admission to the exhibition is free for all registered participants.

Conference Information

Photo Taking, Audio Recording and Video Shooting

No photo taking, audio recording and video shooting are allowed in the meeting rooms for this Conference unless permission is granted.

Beeping Devices

Please switch off mobile phones and beeping devices (or use the vibrant mode) during the lectures and presentations.

Tea Breaks & Lunches

Registered delegates are entitled to tea breaks and lunches during the two-day Conference. Tea breaks and lunches will be severed at Ballroom, 3/F on Saturday & Sunday, 20 - 21 October 2012.

Academic Accreditations

	20 October 2012	21 October 2012	Max.
	CME / CNE / CPD Points		
Hong Kong College of Anaesthesiologists (Non-Ana)	6.5	6.92	13.42
Hong Kong College of Community Medicine	6	6	10
College of Dental Surgeons of Hong Kong (Cat. B)	6.5	7	-
Hong Kong College of Emergency Medicine	6	6	12
Hong Kong College of Family Physicians (Cat. 5.2)	5	5	10
College of Obstetricians & Gynaecologists	6.5	6.5	-
College of Ophthalmologists of Hong Kong (Passive)	3	3	4
College of Orthopaedic Surgeons (Cat. B)	5	5	-
College of Otorhinolaryngologists (Cat. 2.2)	3.5	3.5	7
Hong Kong College of Paediatricians (Cat. A)	6	6	-
Hong Kong College of Pathologists (PP)	3	3.5	6.5
Hong Kong College of Physicians	6.5	7	-
Hong Kong College of Psychiatrists (PP/OP)	6	6	12
Hong Kong College of Radiologists (Cat. B)	6.5	6.5	-
College of Surgeons of Hong Kong (Passive)	6	6	12
MCHK CME Programme	5	5	10
CNE for Nurses, Union Hospital	16	16	-
CPD for Physiotherapists	10		-
CPD for Diagnostic Radiographers	Pending		-

Best Abstract Competition

Best Abstract Competition will be held on Saturday 20 October 2012 (07:45 – 09:00) at the Ballroom, 3/F. Three abstracts will be selected to receive awards in the Faculty Dinner at Peking Garden Restaurant, Tsim Sha Tsui, Kowloon on Saturday 20 October 2012 (19:30 – 21:30).

Best Clinical Case Competition

Best Clinical Case Competition will be held on Sunday 21 October 2012 (15:30 – 16:55) at the Ballroom, 3/F. Three clinical cases will be selected to receive awards after the Competition.

Disclaimer

Whilst every attempt has been made to ensure that all aspects of the Conference announced will take place as scheduled, the Organizing Committee reserves the right to make changes at any time should the need arise.

Liability

The Organizing Committee will not be liable for personal accident and/or loss or damage to the property of participants during the Conference. Participants should make their own arrangements with respect to personal insurance.

Floor Plan

3/F, Sheraton Hong Kong Hotel & Towers

- **Main Conference:**
  Ballroom A
- **Press Conference & Hands-on Workshop**
  (21 October 2012)
  Tang Room
- **Tea Break & Exhibit:**
  Ballroom B & C
- **Registration & CME/CNE Sign Up:**
  Pre-Function Area
- **Slide Preview Room:**
  Bridegroom Room
- **Secretariat:**
  Bridal Room

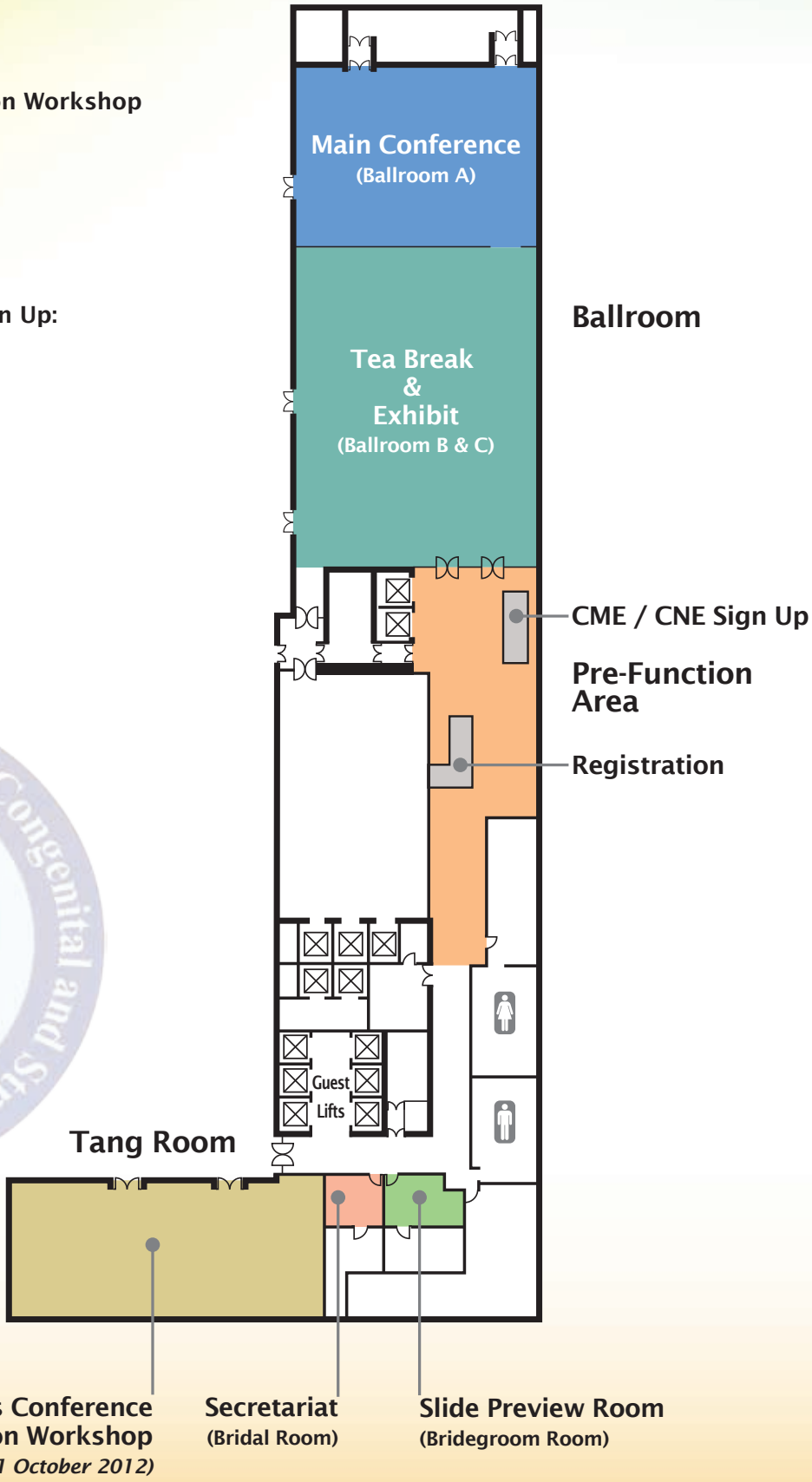

Exhibition

Ballroom, 3/F, Sheraton Hong Kong Hotel & Towers

- **A** Medtronic International Ltd.
- **B** St. Jude Medical (HK) Ltd.
- **C** Abbott Vascular
- **D** Occlutech International AB
- **E** Boehringer Ingelheim (HK) Ltd.
- **F** Philips Electronic Hong Kong Ltd - Healthcare
- **G** Johnson & Johnson (HK) Ltd.
- **H** Lifetech Scientific Co. Ltd.
- **I** McBarron Book Co. Ltd.
- **J** Novartis Pharmaceuticals (HK) Ltd.
- **K** AstraZeneca Hong Kong Ltd.
- **L** Merck Sharp & Dohme (Asia) Ltd.
- **M** Sanofi-aventis Hong Kong Ltd.
- **N** Takeda Pharmaceuticals Taiwan Ltd. (Hong Kong Branch)
- **O** OrbusNeich Medical Co. Ltd.
- **P** Boston Scientific Hong Kong Ltd.

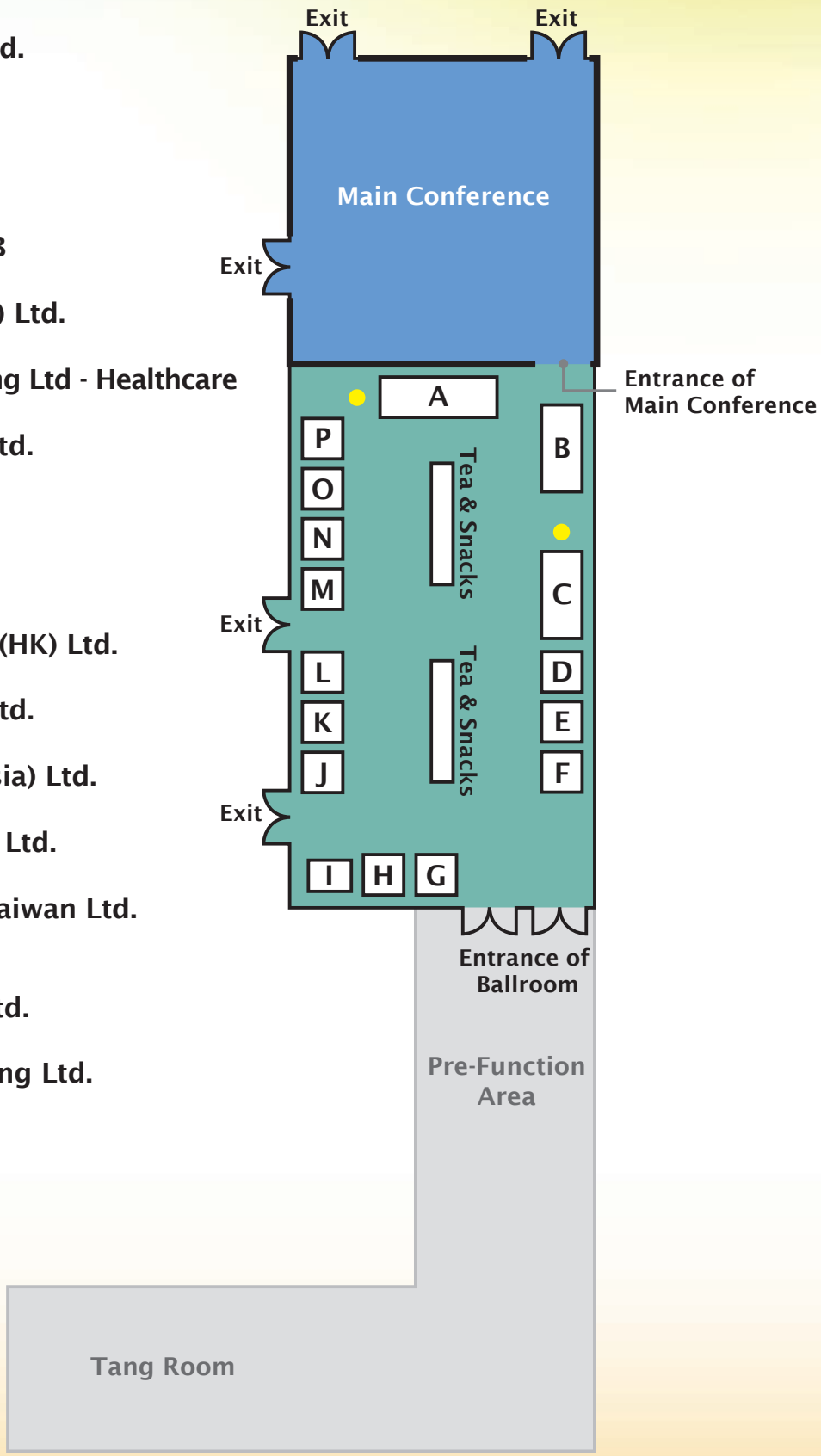

Absorb

Bioresorbable Vascular Scaffold System

Design Elements



Bioresorbable Scaffold

Poly (L-lactide) (PLLA)

Based on proven MULTI-LINK pattern

Naturally resorbed, fully metabolized*



Bioresorbable Coating

Poly (D,L-lactide) (PDLLA)

Naturally resorbed, fully metabolized

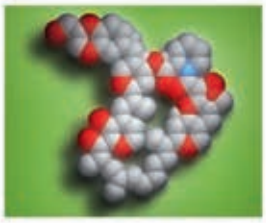

Everolimus

Similar dose density and release rate to XIENCE V

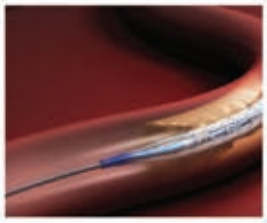

XIENCE V Delivery System

World-class deliverability

**Small platinum markers at scaffold edges remain for fluoroscopic landmarking.*

Restore Freedom

Abbott
A Promise for Life

TERUMO®

Contributing to Society through Healthcare

TERUMO CORPORATION

Best Abstract & Clinical Case Competitions

Best Abstract Competition

Date : **Saturday 20 October 2012**
Time : **07:45 – 09:00**
Venue : **Ballroom, 3/F, Sheraton Hong Kong Hotel & Towers**

Sequence (Time Slot)	Abstract Title	Name & Origin
07:45 – 08:00	Percutaneous Closure of Ascending Aortic Pseudoaneurysm Using Amplatzer Septal Occluder : A Report of Two Cases	Munesh Tomar *(India)*
08:00 – 08:15	Assessment of Left Atrial Appendage Ejection Fraction in Three Dimensions with 64 Slice Computed Tomography	Hidehiko Hara *(Japan)*
08:15 – 08:30	Vascular Plugs: Our Experience from Nine Cases	Manoj Kumar Rohit *(India)*
08:30 – 08:45	Predictors of Residual Functional Tricuspid Regurgitation after Transcatheter Atrial Septal Defect Closure: Importance of Pre-Closure Tricuspid Valve Anatomy	Fang Fang *(Hong Kong)*
08:45 – 09:00	Medical and Surgical Hybrid Therapy for Complex and Cyanotic Congenital Heart Defects Patients with Major Aortopulmonary Collateral Arteries	Yao-ling Ma *(China)*

** Three abstracts will be selected to receive awards in the Faculty Dinner on 20 October 2012*

Best Clinical Case Competition

Date : **Sunday 21 October 2012**
Time : **15:30 – 17:00**
Venue : **Ballroom, 3/F, Sheraton Hong Kong Hotel & Towers**

Sequence (Time Slot)	Case Title	Name & Origin
15:30 – 15:45	Case of SOB in a 83 Year Old Lady	Daniel Fong *(Hong Kong)*
15:45 – 16:00	How to Treat a Mitral Paravalvular Leak?	Jason Ko *(Hong Kong)*
16:00 – 16:15	Coarctation of Aorta; My Disaster	Manoj Kumar Rohit *(India)*
16:15 – 16:30	Residual Severe Echo Contrast After Successful Implantation of ACP in a Patient	Jung-sun Kim *(Korea)*
16:30 – 16:45	Man Against the Rock	Adrian Cheong *(Hong Kong)*
16:45 – 17:00	Percutaneous Transcatheter Embolization of Pulmonary Arteriovenous Fistula	Yao-ling Ma *(China)*

** Three clinical cases will be selected to receive awards after the competition*

Percutaneous Transcatheter of Perimembranous Ventricular Septal Defect With Ductal Occluder in Viet Nam

Nguyen Lan Hieu, MD, PhD

Vietnam Heart Institute, Hanoi Medical University, Vietnam

OBJECTIVES: The study attempted to report the initial safety and efficacy results of transcatheter closure of perimembranous ventricular septal defects (PmVSDs) using the ductal occluder in Viet Nam.

BACKGROUND: The most common congenital heart disease is PmVSD. Surgicalrepair is widely accepted, but still carries a small but definite risk of morbidity and mortality.

METHODS: Between October 2008 and July 2011, a total of 267 patients with PmVSD underwent an attempt of transcatheter closure under transthoracic echocardiographic guidance in three heart center in Viet Nam. All patients were followed up until August 2011, an average of 15.25 months. The median age was 12. 75 years (range, 8 month to 54 years) and median weight was 27.31 kg (range, 5.8 to 78 kg); the median VSD size as assessed by ventriculography was 7.05 mm at left ventricular side (range, 2.0 to 24 mm).

RESULTS: The attempt to place a device was successful in 253 patients (94.76%). The median right ventricular–sided device size used was 7.35 mm, 7.78 mm, 6.97 mm with Amplatzer PDA, Cocoon PDA, Searcare PDA respectively (range, 6 to 18 mm). The complete closure rates by transthoracic echocardiography at 24 h, 1 month, 3 months and 6 months (transthoracic) were 92.88%, 94.47%, 95.65%, and 100%, respectively. No death occurred. Two patients (0.79%) had serious adverse events of post implantation complete heart block; pacemaker was indicated in one patient. No other patient encountered serious adverse events during the follow-up.

CONCLUSIONS: Transcatheter closure of a PmVSD with ductal occluder is technically feasible and seems safe enough in children to warrant continuation of clinical trials to assess the long-term safetyand efficacy.

PFO Closure after the CLOSURE I trial

Peter Ruygrok, MD

Auckland City Hospital, New Zealand

A patent foramen ovale (PFO) has been identified to be more common in patients with cryptogenic stroke (~50%) than in the general population (~25%) suggesting an association. The published data suggesting that PFO closure significantly reduces the chance of recurrent stroke and TIA have been longing for corroborative information from randomised studies which have been very slow to recruit appropriate patients. The CLOSURE I study which randomised 909 patients over a period of 7 years failed to show superiority of percutaneous closure over medical therapy. Some criticisms of the study will be discussed. The results of the 980 patient RESPECT trial will be presented at TCT.

Where does that leave us with respect to current best practice PFO closure? At present it is generally felt that PFO closure can be considered in carefully selected patients following one or more neurological events and risk factors that are associated with a higher chance of recurrent events (e.g. aneurysmal septum, recurrent DVT, other peripheral embolic events, evidence of embolic event in greater than one vascular territory on MRI scan). A decision algorithm will be presented. There is a clear and pressing need for more data to elucidate the best approach to the treatment of patients with cryptogenic stroke and PFO.

Abstracts of Lectures

The New Era of the Interventional Imager: Multimodality Imaging in the Cath Lab

Murat Tuzcu, MD

Cleveland Clinic, USA

Innovation in interventional cardiology continues to progress at a rapid pace, most recently with the evolution of structural cardiac interventions. The developments in these procedures and techniques have necessitated the concomitant advancement of cardiovascular imaging. While fluoroscopic imaging in the cardiac catheterization laboratory is routine, the 2D nature of the data provided is often inadequate for complicated structural interventions. Rather, meticulous pre-procedural planning and intra-procedural guidance using multidetector computed tomography (MDCT), and twodimensional(2D) and three-dimensional (3D) echocardiography is usually necessary.

While procedural transesophageal or intracardiac echocardiography (TEE or ICE) is often used, they are often limited in their ability to help guide catheters and devices. This may be due to variability in image quality and difficulty in determining the proper image plane; they require simultaneous visualization by the operator of an additional screen displaying echocardiographic images; and TEE is uncomfortable for patients who are not intubated for the procedure. The ability to use the 3D images obtained by MDCT to provide real-time procedural guidance in the cardiac catheterization laboratory therefore holds tremendous potential to improve procedural success and also reduce procedural time, fluoroscopy dose, and duration of TEE use. The modern catheterization laboratory C-arm has the ability to acquire CT-like images. The process of overlaying markings made on a pre-procedural CT to the realtime fluoroscopy using this technology allows visualization of the targets precisely. All of the atheter based structural heart disease treatments including balloon mitral valvotomy, mitral clip procedure, transcatheter aortic valve replacement, ASD, PFO, VSD closures, paravalvular leak closures all rely on multimodality imaging in the Cath Lab.

Who Will Benefit from Percutaneous Management of Mitral Regurgitation? An Imaging Guide to Management

James Thomas, MD, FACC, FASE, FESC, FAHA

Cleveland Clinic, USA

Imaging plays a key role in selecting appropriate patients for percutaneous management of mitral regurgitation and providing real-time guidance of the intervention. Echocardiography can identify the mechanism of regurgitation and quantify the severity. Management with the MitraClip is feasible in both organic and functional MR (either from ischemic or dilated cardiomyopathy) but requires at least 2 mm of coaptation overlap, a tenting distance from the mitral annulus of no more than 11 mm, a flail width of <15 mm, and no more than a 10 mm gap between the flail leaflet and the opposing one. Severity is graded in standard fashion using proximal convergence analysis to calculate regurgitant orifice area with pulmonary hypertension providing important evidence for severity. MRI can aid in quantification, while cardiac CT is useful for determining candidacy for mitral annular remodeling (localizing coronary sinus relative to mitral annulus and left circumflex artery). Transesophageal echocardiography is critical for guiding the intervention, particularly with realtime 3D imaging. Trans-septal puncture can be safely guided, and the interventionalist can use the imaging in a very intuitive way to grasp the leaflets. Once the clip is in place, echo can quantity residual MR and transmitral gradient, providing crucial evidence for placement of a second clip. In follow-up, echo is used in a similar fashion as after mitral surgery. It will be important to provide close monitoring of these patients, as the natural history of these novel technologies is yet to be defined.

Abstracts of Lectures

Surgical Techniques of Mitral Valve Repair

Lars Svensson, MD, PhD

Cleveland Clinic Cleveland, OH

Ever since the early experience of cloned mitral valve valvotomy the field of mitral valve repair surgery has evolved. Incisions have gone from full sternotomy to paramedian incision to J incision to right mini-thoracotomy to robotic repair. At the same time the mitral valve repair techniques have also evolved from complete rings to bands and also to more frequent use of artificial chordae. At the same time, results have improved and long-term durability is excellent, particularly for posterior leaflet repairs.

Evolution of Aortic Valve Surgery

Lars Svensson, MD, PhD

Cleveland Clinic, USA

Just like mitral valve surgery, aortic valve procedures have evolved. The more recent developments are the increasing use of aortic valve leaflet repairs, particularly for bicuspid valves, root reconstructions with the modified David procedure, and also newer replacement method such as better valves and the transcatheter devices. Some of these will be reviewed.

Procedural Guidance of TAVR: How to Assure it Goes Right and What to do if it doesn't

James Thomas, MD, FACC, FASE, FESC, FAHA

Cleveland Clinic, USA

At the Cleveland Clinic, echocardiography is used in all TAVR cases. While it is certainly possible to position the device without TEE guidance (as is commonly done in Europe), we find it a useful adjunct to fluoroscopy in uncomplicated cases and absolutely essential when hemodynamic instability occurs after implantation. In such cases, there may only be seconds to react to whatever has gone wrong. Although comprehensive TTE, TEE, and CT imaging is expected to be performed prior to the intervention, we always perform a survey to confirm findings, particularly to assure accurate measurement of the aortic annular dimension. X-plane imaging is particularly helpful for measuring the noncircular annulus and also for optimally positioning the valve across the valve. Once the valve is deployed, one must immediately assess for the presence of aortic regurgitation. It is common to have trivial central regurgitation, and with the degree of annular calcification commonly seen in these cases, a mild degree of paravalvular may also be observed. More severe central AR may result from the failure of one of the leaflets to close, which may resolve with gentle probing with a catheter. If not, then a redo valve- in-valve procedure may be required. For significant paravalvular regurgitation, reballooning may be helpful. With hemodynamic instability, one must quickly exclude: aortic dissection, cardiac tamponade, displacement of the device into the LV or aorta, regional or global LV dysfunction, severe mitral regurgitation, and LVOT obstruction.

Abstracts of Lectures

Hybrid Approach to Aortic Arch Surgery

Lars Svensson, MD, PhD

Cleveland Clinic, USA

In the early era of aortic arch surgery, off-pump bypass procedures were used with occlusion of aneurysms. More recently, the modern variants are bypasses and hybrid stent grafting. Various options can be used for the arch but for most of our patients we have found the use of the first stage elephant trunk procedure followed by either open or hybrid stenting of the second stage to be safer and more effective for dealing with arch aneurysms. These approaches will be discussed.

TAVI 2012 and Beyond

Murat Tuzcu, MD

Cleveland Clinic, USA

Aortic stenosis affects a significant number of patients worldwide, and carries a dismal prognosis once symptoms develop. Unfortunately, a large number of patients present a prohibitive risk for surgical aortic valve replacement. Therefore, transcatheter aortic valve implantation has emerged as a promising technology for providing treatment to this group of patients. Currently available valves include the balloon-expandable Edwards SAPIEN valve (Edwards Lifesciences, Irvine, CA), which is usually implanted via a transfemoral or transapical approach, and the selfexpanding CoreValve ReValving system (Medtronic, Minneapolis, MN), which uses only the transfemoral route. Early experience with the procedure performed on a compassionate-use basis was encouraging, and led to a number of first-in-man and feasibility studies. These trials demonstrated the safety and efficacy of valve implantation and led to CE (European Conformity) mark approval of both valves in Europe. Use of the SAPIEN valve in the United States is limited to the recently completed PARTNER (Placement of Aortic Transcatheter Valve) randomized trial comparing transcatheter and surgical aortic valve replacement in high-risk patients, and its post-trial registry. The CoreValve is not yet available in the United States. With improved device technology, better understanding of patient selection and preand periprocedural imaging, and greater procedural experience, widespread diffusion of transcatheter aortic valve implantation is expected.

Abstracts of Lectures

Challenges in Clinical and Echocardiographic Assessment of AS – Who is a Candidate for TAVR

Brian Griffin, MD

Cleveland Clinic, USA

Assessment of patients who are symptomatic and who have severe aortic stenosis clinically and by conventional echocardiographic measurements is relatively straight forward. Intervention is generally indicated and the decision now is whether there significant other issues that might make surgical replacement of the valve high risk. Many US centers use the Society of Thoracic Surgical Scoring (STS) System to address surgical risk whereas other centers use the Euroscore. Assessment of risk with any of these scores is not always reliable and there are some important comorbidities not included in these scores. These include significant radiation exposure which is an increasing part of our valve disease practice and which is associated with worse outcomes especially in regard to reoperation and thoracic complications such as recurrent effusion. These patients may do well with TAVR and are increasingly referred for this as this obviates the thoracic complications. Significant atheroma or calcification of the aorta may also be a consideration in selecting TAVR. Deciding whether the aortic stenosis is critically involved in symptoms in the patient with LV dysfunction, low gradients and severe aortic stenosis by valve area remains an important but challenging area. Dobutamine echocardiography is helpful in deciding who has truly severe aortic stenosis versus who has a cardiomyopathy and mild AS that will not benefit from valve intervention. In this paper, we will discuss how to assess aortic stenosis, how to differentiate low gradient severe AS from cardiomyopathy and mild AS, and how to define suitable candidates for surgical vs transfemoral or transapical AVR.

CoreValve Implantation: Tips & Tricks

Jan-malte Sinning, MD

University of Bonn, Germany

Paravalvular aortic regurgitation (PAR) negatively impacts the prognosis following transcatheter aortic valve replacement (TAVR) with dramatically increased morbidity and mortality in patients suffering from more-than-mild PAR. As transcatheter heart valves are implanted in a sutureless fashion using oversizing to anchor the prosthesis stent frame at the level of the virtual aortic annulus, stent frame underexpansion due to heavily calcified cusps, suboptimal placement of the prosthesis, and/or annulusprosthesis-size mismatch due to malsizing can contribute to paravalvular leakage. In contrast to open heart surgery, TAVR does not offer the opportunity to measure the aortic annulus under direct vision during the procedure. Therefore, the dilemma before each TAVI procedure is the appropriate sizing of the dimensions of the aortic annulus and to choose not only the size but also the THV type (self-expanding vs. balloon-expandable) that fits the given anatomy best.

Since precise echocardiographic quantification of PAR in TAVR patients remains challenging especially in the acute implantation situation, a multimodal approach for the evaluation of PAR with use of hemodynamic measurements and imaging modalities is imperative to precisely quantify the severity of aortic regurgitation immediately after valve implantation and to identify patients who will benefit from corrective measures such as post-dilatation or valve-in-valve implantation. Every measure has to be taken to prevent or reduce PAR in order to provide satisfying longterm clinical outcome.

Abstracts of Lectures

Clinical Value of 3D Echo: Volumes and Valves

James Thomas, MD, FACC, FASE, FESC, FAHA

Cleveland Clinic, USA

Over the past 30 years, tremendous advances have been made in threedimensional echocardiography, progressing from sonic to electromagnetic localizers to reconstruction of linear or rotational collections of 2D echo to the present day, when massively parallel processing allows 3-dimensional images to be produced in real time using a 2D phased array of crystals. Although 3D echocardiographic measurement of LV volume has been shown more accurate than 2D methods, there is systematic underestimation of volume in comparison to MRI due to different handling of endocardial trabeculations. Use of ultrasound contrast can effectively eliminate this underestimation. 3D echo also excels at visualization of nonplanar structures such as valves. By using multiplanar reconstruction, it is possible to define exactly which scallop of the mitral valve is involved in the pathology. Such imaging can also be used to localize the size and point of attachment of vegetations and other cardiac masses. 3D TEE has become an important prerequisite for guidance of interventional procedures. Several examples will be shown, including ASD and PFO closure, mitral and aortic valve procedures and occlusion of paravalvular leaks. Similar to the situation in the operating room, the presence of 3D echo allows interventionalists to take on much more challenging tasks than could otherwise be undertaken.

Device Closure of Paravalvular Leak – Imaging in Patient Selection and Device Placement

Brian Griffin, MD

Cleveland Clinic, USA

Paravalvular leak occurs relatively infrequently following successful surgical implantation of a prosthetic valve. Paravlavular leakage postoperatively may occur for a number of reasons. These include infection/endocarditis in which case most often surgical debridement and a new valve may be placed. Other causes may include expansion of a smaller postop leakage, and suture degeneration. Suture degeneration is more likely at the mitral valve and often relates to annular calcification which may fray the sutures directly. Paravalvular leakage may cause severe hemodynamic effects and may cause intravascular hemolysis that may be severe. Assessment of paravalvular leak requires transesophageal echocardiography with 3D capability that may outline the defect(s) well. Parvalvular leakage is often occult and easily underestimated by transthoracic echocardiography as the regurgitant jets may be very eccentric and not seen in standard views. Isolation of the proximal convergence zone is often helpful both in localization and also in quantification of severity. As jets may be multiple, careful evaluation around the annulus using 15 degree intervals on the multiplane probe is essential so as not to miss additional areas of leakage. Determining what is suitable for percutaneous closure is often based on the clinical scenario: infection, hemolysis, site and size of defect. Imaging by TEE is critical in determining the placement of the closure devices and in assessing the clinical impact on the regurgitation. Imaging at the aortic position is often more challenging than at the mitral. We will discuss assessment of paravalvular leakage with imaging both before and during device placement in this talk.

Abstracts of Lectures

Diagnosis and Management of Post-myocardial Infarction Ventricular Septal Defects

Peter Ruygrok, MD

Auckland City Hospital, New Zealand

As the treatment of acute myocardial infarction has evolved from conservative management to thrombolysis and in more recent times, primary angioplasty, the incidence of ventricular rupture, in particular post infarction ventricular septal defect, appears to have fallen. The clinical presentation and investigation of post infarction VSD, the natural history as well as surgical and percutaneous interventional management, and outcomes will be presented. Very limited published information is available from small series reports with the inherent limitation of survivor selection bias. Survival is clearly enhanced by intervention whether it be surgical or percutaneous. Overall outcomes remain suboptimal but do appear to be significantly better in the absence of cardiogenic shock and if the procedure can be deferred, factors which are clearly related. Further research is required in this difficult field.

Pulmonary Valve Disease in Congenital Heart Disease: How Bad is the Problem?

Brian Griffin, MD

Cleveland Clinic, USA

The leading causes of pulmonary valve disease in both pediatrics and adults are of congenital origin. Pulmonic stenosis may occur as an isolated condition or be part of a more complex congenital problem such as tetralogy of Fallot. Doppler echocardiography is the technique of choice in identifying those with significant valvar or subvalvalar pulmonic stenosis. Intervention is not usually indicated in isolated PS unless the patient has symptoms and moderate PS or asymptomatic severe PS. Balloon valvuloplasty is both safe and highly effective in treating most instances of severe PS. Complex congenital heart disease associated with pulmonic stenosis is often treated with valvotomy at the time of corrective surgery. This in time may give rise to severe pulmonic insufficiency which may cause RV dilatation and failure. Poor long term outcomes arising from sudden death may occur in this clinical scenario. This is an instance where both clinical examination and a standard Doppler echocardiogram may fail to easily identify the precise cause of the problem as the diastolic flow across the pulmonic valve in this situation may be of low velocity and may be hard to auscultate and the low velocity flow is often misinterpreted as normal laminar flow by Doppler. Careful evaluation of patients with RV enlargement particularly if it is increasing in size is necessary and should involve MRI and MRA of the RV outflow. This is helpful in not only assessing severity of pulmonic insufficiency but also of RV function. We will discuss the appropriate evaluation pf pulmonary valve disease by various imaging techniques in this talk.

TrenD and its Expanding Indications

Steven SL Li, MBBS(HK), FHKAM (Med), FRCP (Glasg), FRCP (Edin), FRCP (Lond), FACP, FESC, FACC, Specialist in Cardiology

Heart Centre, Union Hospital, Hong Kong

Resistant hypertension has been a challenging medical problem to handle. Transcatheter renal denervation (TRenD) fills this clinical gap where medical therapy often fails to fulfill. Studies have shown that TRenD is a safe and effective procedure with low complication rate. In addition to resistant hypertension, studies on other clinical applications such as congestive heart failure, insulin resistance, chronic renal disease and obstructive sleep apnea are ongoing.

Abstracts of Lectures

MitraClip

Boron CW Cheng, MD
Hong Kong

MitraClip is the treatment of choice for severe mitral regurgitation. Which group of patients would benefit from this new procedure and what would be the results? The latest research data will be presented.

TAVI "Lady with an Exceptional Anatomy"

Jan-malte Sinning, MD
University of Bonn, Germany

In this case, we report on a 83-year-old female patient suffering from dyspnea NYHA III-IV due to severe symptomatic aortic stenosis (logistic EuroSCORE 27.1%). This patient not only had a bicuspid aortic valve but also an ectatic, horizontal aorta hampering the TAVI procedure. Although the annulus in this patient was very ovalshaped (26 x 20 mm2), the prosthesis could be implanted successfully with a good procedural result and only trace AR in the final angio.

Transcatheter Closure of Left Ventricular Posterior Wall Rupture after Myocardial Infarction

Yun-ching Fu, Ming-chih Lin, Sheng-ling Jan, MD
Section of Pediatric Cardiology, Taichung Veterans General Hospital, Taiwan

Introduction: Left ventricular rupture after acute myocardial infarction results in congestive heart failure and risks of stroke and mortality. Traditional surgical repair carries certain risks.

Case report: A 77 year-old man suffered from acute myocardial infarction 2 months ago. He received stent implantation for left circumflex coronary artery at that time but developed transient ischemic attack with right hemiparesis 2 weeks ago. Because of congestive heart failure signs including shortness of breath and ankle edema, he was sent to our hospital. Chest X-ray revealed cardiomegaly with right pleural effusion. Chest CT showed the rupture of left ventricular posterior wall with a 7.2-cm pseudoaneurysm formation. The rupture defect was 1.6 x 1 cm in diameter, which was close to the mitral papillary muscle. After informed consent was obtained, we successfully closed the defect percutaneously with a 19-mm Amplatzer septal occluder. The procedure was 110 minutes and the NYHA functional class improved from IV to II.

Discussion: Transcatheter device closure of left ventricular rupture after acute myocardial infarction is technically feasible, safe and effective.

Device Closure of LV lateral Wall Rupture Cases

Peter Ruygrok, MD
Auckland City Hospital, New Zealand

Left ventricular free wall rupture is a usually fatal complication of acute myocardial infarction and is reported to occur in 1% of cases. On rare occasions patients have survived acute repair surgery. A small number of patients live through the acute event and develop a LV pseudoaneurysm. This presentation describes a series of three cases with a chronic lateral wall rupture resulting in a pseudoaneurysm subsequently closed with Amplatzer closure devices. The procedure and outcomes are discussed.

Xience

Xpedition

Everolimus Eluting
Coronary Stent System

Smooth Tracking

XIENCE Safety*

Smooth

The most agile XIENCE. **Ever**.

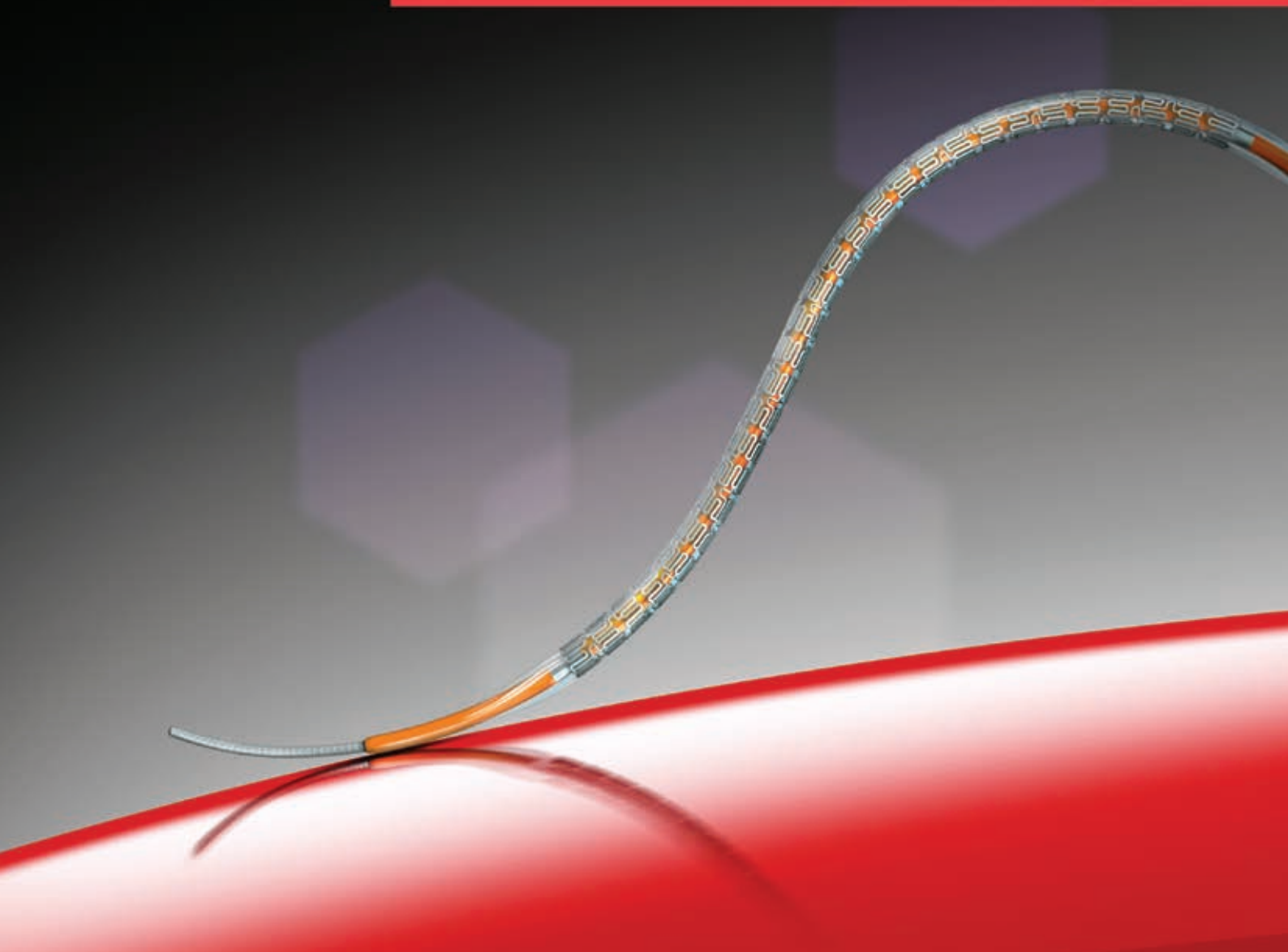

*Based on ST rates from SPIRIT II, SPIRIT III and SPIRIT IV.
XIENCE Xpedition IFU and data on file at Abbott Vascular.

Information contained herein is for Europe, Middle East and Africa, and Asia Pacific only.

Abbott
A Promise for Life

Perfecting Performance

Figulla® Flex II The Third Generation ASD and PFO Occluders



www.occlutech.com

Occlutech®

INTRODUCING EFFIENT FOR ACS-PCI PATIENTS

EFFIENT plus ASA provides STRONGER PROTECTION AGAINST CV EVENTS

vs clopidogrel plus ASA in ACS PCI[1]

HKGEFF082012001 04

Reference:
1. Wiviott SD et al. N Engl J Med 2007;357:2001-2015.



Effient®
prasugrel tablets

Lilly

Eli Lilly Asia, Inc.
Suites 2501-9, 25/F, Tower 2, Times Square, 1 Matheson Street,
Causeway Bay, Hong Kong.
Tel: (852) 2572 0160 Fax: (852) 2572 7893

THE STRENGTH YOU DEMAND, THE PROTECTION THEY NEED

Percutaneous Closure of Ascending Aortic Pseudoaneurysm Using Amplatzer Septal Occluder : A report of Two Cases.

Munesh Tomar, Sushil Azad, Naresh Trehan

Department of Pediatric Cardiology and Congenital Heart Disease, Medanta-The Medicity, Gurgaon, India

Introduction: Pseudoaneurysm of ascending aorta is unusual & potential fatal complication of cardiovascular surgery. It usually occur at the sites of aortic wall disruption. The aortic suture lines made during aortic valve replacement or coronary artery bypass graft insertion site or cannulation site are potential locations. Surgery for these condition may be complicated by adhesion and rupture of these aneurysm during sternotomy. We report our experience with two such patients who were treated with percutaneous approach using Amplatzer septal occluder.

Case Report: Two patients one 35 years old and other 50 years old who underwent Bentall surgery now presented with chest pain radiating to back and flanks. Echocardiography revealed large fluid filled cavity adjacent to ascending aorta confirmed by contrast enhanced computed tomography and diagnosed as a pseudoaneurysm . The communication was between distal descending aorta and graft prosthesis measured 9mm and 8 mm . Surgery was believed to carry a very high risk so a percutaneous approach was planned and both underwent closure of the communication between ascending aorta and pseudoaneurysm using Amplatzer Septal occluder successfully.

Comments: Pseudoaneurysm formation after thoracic aorta replacement develop at late stage. Although it can be secondary to trauma or infection, previous cardiac surgery is most frequent cause. Most pesudoaneurysm arise at the site of aortic wall disruption. It occurs in less than 0.5% of all cardiac surgical case It is potential fatal complication. Surgery may be associated with high morbidity and mortality. Endovascular treatment emerging as promising option in treating these condition with less complication and reduced risk of morbidity and mortality should be considered as a feasible alternative.

Predictors of Residual Functional Tricuspid Regurgitation after Transcatheter Atrial Septal Defect Closure: Importance of Pre-Closure Tricuspid Valve Anatomy

Fang Fang, Xiu-xia Luo, Qing-shan Lin, Yan-chao Zhang, Joey S.W. Kwong, Xin-jiang, Cheuk-man Yu, Yat-yin Lam

Division of Cardiology, Medical & Therapeutic Department, Chinese University of Hong Kong, Hong Kong

INTRODUCTION: Although chronic right heart volume overloading is relieved by device closure of atrial septal defect (ASD), the change of functional tricuspid regurgitation (TR) remains unclear. This study aimed to determine the prevalence and predictors of persistent TR after ASD transcatheter closure.

METHOD: Comprehensive transthoracic echocardiography was performed in 61 consecutive secundum ASD patients (46±17 years, 16 males) shortly before and at 3 months after device closure of ASD. Tricuspid annulus diameter, tenting area, tenting height, distal tricuspid septal leaflet angle (TSLA), right and left ventricular volumes were quantified. Persistent TR was defined as more-than-mild TR with semiquantitative method at 3-month follow-up. The pulmonary arterial systolic pressure was measured with standard fluid-filled catheters and the ratio of pulmonary to systemic flow was calculated with oximetry by use of Fick's principle.

RESULTS: TR was significantly reduced after ASD device closure at 3-month follow-up (TR vena contractor: 0.4±0.3 versus 0.3±0.2 cm, p=0.005). However, persistent TR was detected in 30 patients (49%). At baseline, these patients had larger right ventricle, greater tricuspid tenting height, tenting area and TSLA as well as more dilated tricuspid annulus compared to those without residual TR (Table). Multivariate logistic regression revealed that tricuspid annulus diameter [odds ratio (OR): 10.68, p=0.026] and TSLA (OR: 1.19, p=0.026) were the independent predictors for the persistent TR. From the receiver operating characteristic (ROC) curve, tricuspid annulus diameter of 3.4 cm (sensitivity 97%, specificity 84%, AUC 0.86, p<0.001) and an TSLA of 30 ° (sensitivity 100 %, specificity 71%, AUC 0.83, p<0.001) were associated with persistent functional TR after ASD closure. Assessment of TSLA showed an incremental value over tricuspid annulus diameter for predicting persistent TR (X^2=16.6 vs.12.3, p=0.001).

CONCLUSIONS: At 3 months after ASD closure, around half of adult subjects were found to have persistent TR. Tricuspid annulus diameter and TSLA appeared to be independent predictors for the persistent TR. Tricuspid structural changes are believed to play a pivotal role in this phenomenon.

Medical and Surgical Hybrid Therapy for Complex and Cyanotic Congenital Heart Defects Patients with Major Aorta Pulmonary Collateral Arteries

Zhang Gangcheng, Shen Qunshan, Yao Yi, Tao Liang

Abstract: Object To summary the clinical therapy experience of medical and surgical hybrid therapy for complex and cyanotic congenital heart defects patients with major aorta pulmonary collateral arteries, and to explore its therapy significance , operating skills and security. Method To retrospectively analyze 41 cyanotic CHD patients with aorta pulmonary collateral arteries, whose age ranged from 1 to 28,weight ranged 18.2±7.8kg . All of them accepted CT to diagnosis, 38 of which were performed interventional catheterization to close the collateral arteries, and 3 cases was found the collateral arteries after surgery and was closed by catheterization. All of them were performed one stage repair. Result 37 of them were cured, among four dead patients, one died from lung infection, and three cases were due to heart failure. The diameter of the collateral arteries ranged from 2.5mm to 9.4mm. Every patient was put 3 to 21 spring circles. 3 cases were performed the second closure because of arteries recanalization. 14 cases had lung infection, 3 suffered from lung edam, and 2 had lung flooded. Conclusion complex and cyanotic congenital heart defects patients who have major aorta pulmonary collateral arteries can accept medical and surgical hybrid therapy to handle the collateral arteries. This method is effective, easy and safe, what's more, repeatable which can reduce the complication and depress the mortality.

Key words: cyanotic; congenital heart defects; major aorta pulmonary collateral arteries; hybrid therapy

Acknowledgements

The Organizing Committee of the 3rd Asia Pacific Congenital and Structural Heart Intervention Symposium 2012 (APCASH 2012) wishes to express its sincere appreciation to the following companies/institutions for their generous support in making the Conference a great success:

Live Transmission Centres

Grantham Hospital, Hong Kong
Rigshospitalet, Copenhagen University Hospital, Denmark

Diamond Sponsor

Medtronic International Ltd.

Platinum Sponsor

St. Jude Medical (Hong Kong) Ltd.

Gold Sponsor

Abbott Vascular

Major Sponsors

AstraZeneca Hong Kong Ltd.
Biosensors Interventional Technologies Pte Ltd.
Boehringer Ingelheim (Hong Kong) Ltd.
Boston Scientific Hong Kong Ltd.
Eli Lilly Asia Inc
Johnson & Johnson (Hong Kong) Ltd.
LifeTech Scientific (Shenzhen) Co. Ltd.
McBarron Book Co. Ltd.
Mekim Ltd.
Merck Sharp & Dohme (Asia) Ltd.
Novartis Pharmaceuticals (HK) Ltd.
Occlutech International AB
Orbusneich Medical Co. Ltd.
Philips Electronics Hong Kong Ltd. – Healthcare
Roche Diagnostic (Hong Kong) Ltd.
Sanofi-aventis Hong Kong Ltd.
Takeda Pharmaceuticals Taiwan Ltd. – Hong Kong Branch

Notes

Notes